Cervical Kyphosis Is a Possible Link to Attention-Deficit/Hyperactivity Disorder

Anthony V. Bastecki, DC,[a] Deed E. Harrison, DC,[b] and Jason W. Haas, DC[c]

Abstract

Objective: To discuss the case of a patient who was diagnosed with attention-deficit/hyperactivity disorder (ADHD) by a general practitioner and was treated with chiropractic care.

Clinical Features: A 5-year-old patient was diagnosed with ADHD and treated by a pediatrician unsuccessfully with methylphenidate (Ritalin), Adderall, and Haldol for 3 years. The patient received 35 chiropractic treatments during the course of 8 weeks. A change from a 12° C2-7 kyphosis to a 32° C2-7 lordosis was observed after treatment. During chiropractic care, the child's facial tics resolved and his behavior vastly improved. After 27 chiropractic visits, the child's pediatrician stated that the child no longer exhibited symptoms of ADHD. The changes in structure and function may be related to the correction of cervical kyphosis.

Conclusion: The patient experienced significant reduction in symptoms. Additionally, the medical doctor concluded that the reduction in symptoms was significant enough to discontinue the medication. There may be a possible connection that correction of cervical kyphosis in patients with ADHD may produce a desirable clinical outcome. (J Manipulative Physiol Ther 2004;27:e14)

Key Indexing Terms: *Attention-Deficit/Hyperactivity Disorder; Cervical Traction; Chiropractic Manipulation*

Attention-deficit/hyperactivity disorder (ADHD) is a commonly diagnosed disease in children; the current estimates are 3% to 5% of American children are diagnosed yearly.[1] The nature of the disorder was described more than a century ago.[2] Currently, there are several mechanisms that may cause this disorder. For example, researchers have discussed the relationship between low birth weight,[3] fetal alcohol exposure, and infantile or fetal hypoxia,[4,5] to name only a few. Perhaps the most important possible cause for this case in particular is the correlation between hypoxia and brain disorders such as ADHD. The *Diagnostic and Statistical Manual of Mental Disorders, Fourth Edition* (*DSM-IV*) has specific criteria required for a diagnosis to be made. These criteria include, but are not limited to, inattention to homework or chores, disorderly behavior, fidgeting, leaving their seats frequently, inability to follow through with instructions, and excessive talking, to name only a few. These characteristics must be present in a certain quantity and must be expressed for 6 months or more.[6] It is generally viewed as a disorder characterized by one of inattention and hyperactive and/or impulsive behaviors.[6] Some children who are overactive, inattentive, or impulsive are falsely diagnosed with ADHD.[7]

Generally, if children have these symptoms that interfere with major life activities, the child may be diagnosed with ADHD.[6] Nowhere in the medical literature is it found that, in the diagnosis process for ADHD, children undergo analysis for the detection of spinal and/or postural abnormalities. Children diagnosed with ADHD have a lowered resistance to distraction and decreased attentiveness at the end of the day, and they have been found to have more problems in work-related activities such as schoolwork, homework, and household chores.[8,9] They may be more likely to display antisocial or hyperactive traits in situations in which public scrutiny is increased, such as in court, in church, or in restaurants.[8] Children with ADHD have also been said to have cognitive and physical defects as well. These include decreased physical fitness including gross and fine motor skills, verbal and nonverbal memory skills, and planning and anticipation.[10-13] Furthermore, they may have defects in the self-regulation of emotion. Comorbidity, including obsessive-compulsive disorder, is not uncommon.[8] The traditional medical approach is generally behavior counseling coupled with the application of pharmacologic approaches such as Ritalin (Novartis Pharmaceutical Corp, East Hanover, NJ) (methylphenidate).[14]

[a]Private Practice of Chiropractic, Lexington, Ky.
[b]Private Practice of Chiropractic, Elko, Nev.
[c]Private Practice of Chiropractic, Windsor, Colo.
Submit requests for reprints to: Anthony Bastecki, DC, 3193 Richmond Rd, #202, Lexington, KY 40509.
Paper submitted April 1, 2003; in revised form May 28, 2003.
0161-4754/$30.00
Copyright © 2004 by National University of Health Sciences.
doi:10.1016/j.jmpt.2004.08.007

The child in this case was seen by a primary care physician and not by a mental health expert. This is notable because children seen by mental health experts generally have poorer outcomes, more family burden, and a greater chance of developing comorbidities.[15] This clinical case report will review the results of Clinical Biomechanics of Posture (CBP) protocol on a 5-year-old boy with ADHD.

Case Report

A 5-year-old boy was diagnosed with ADHD at age 2 by a medical doctor. He had been treated unsuccessfully with pharmaceutics during that 3-year period. From his case history, it was noted that there were complications during his delivery process. During a prolonged and stressful labor for both the mother and baby, amniotic fluid had to be aspirated from the child, which ultimately led to a 4-day stay in the neonatal intensive care unit. This could have led to a hypoxic state, which has been implicated as a possible cause of ADHD.[5,6] The child weighed 7 lb 11 oz at birth. The parents reported that the child had not had any other significant traumas, accidents, or injuries.

The initial chief complaints were ADHD, tics, and behavioral issues. From age 2 to the time of chiropractic intervention at age 5, the patient's medical treatment consisted of Ritalin, Adderall (Ortho-McNeil Pharmaceuticals, Raritan, NJ), and Haldol (Shire Pharmaceuticals, New Port, KY). These treatments provided little to no relief of the initial complaints of inattention, disruptive behavior, failure to complete tasks, forgetfulness, facial tics, and inappropriate outbursts at school and church. The parents noted that the facial tics began shortly after the introduction of the Ritalin. During the 3-year period, the medical doctor discontinued the use of Ritalin on a few occasions, although the tics never stopped. The general practitioner who diagnosed the ADHD used the common ADHD checklist for diagnostic confirmation.

Physical examination findings consisted of a significant right lateral head to thorax shift ($-T_x^H$), anterior weight bearing of the head to thorax ($+T_z^H$), observed limited range of motion in both the cervical and thoracolumbar areas without pain, and palpable muscle spasms paraspinally from T2 up to the base of the occiput, as well as pain and tenderness on palpation of the C1 and occipital region bilaterally.

Radiographic studies showed a reversal of the cervical lordosis, a cervical kyphosis measuring at a 12° angle between posterior body tangents drawn on C2 and C7 (Harrison method of cervical analysis) (Fig 1).[16] This can be described as 127% loss of normal cervical lordosis.[17] The Atlas Plane Line angle, measured as the plane of the ring of atlas compared with horizontal, on the lateral cervical was only 8°, whereas a normal value for this angle is 29°.[17] The primary diagnosis was multiple abnormal postural permutations (subluxation), with acquired neck deformity, associated muscle spasms, and neck pain.

Fig 1. *This figure shows the prelateral cervical radiograph of a 5-year-old boy. The absolute rotation angle from C2 to C7 shows a cervical kyphosis of 12°. The atlas plane line measured 8° from horizontal.*

Intervention and Outcome

CBP protocol was used, including mirror image adjustments, mirror image exercises, and mirror image extension-compression traction.[18-22] These spinal adjustment forces were applied via diversified, drop table, and toggle maneuvers. CBP protocol and therapy consisted of specific chiropractic adjustments while placing the patient in his postural mirror image position before and during the application of any adjusting force. This specific CBP patient positioning, termed *mirror image*, was previously described in detail in this journal in 1996.[22] Using a unique postural method originated by Harrison[23] in the early 1980s, the postures of the head, rib cage, and pelvis are determined as rotations and translations. From linear algebra terminology, this patient positioning before spinal forces are applied can be described as an affine transformation.[22] Because rotations, reflections, and translations are matrix functions in mathematics, our use of affine transformation (mirror image) is a composition of twice the inverse function followed by a translation. In the anteroposterior view, this results in moving/stressing the patient's abnormal posture

across the median sagittal plane to the opposite side. In the lateral view of the head and shoulders, this results in moving/stressing the patient's abnormal head posture across the frontal plane to the opposite side of this plane (ie, a vertical plane through the midshoulder). Recently, this CBP procedure has been described inaccurately as only being the use of an inverse posture.[24] Use of an inverse posture would only result in placing a patient in neutral posture before forces are applied, as opposed to going across a body plane to the opposite side.[22]

Because of the severity of the condition and the limited time schedule of the patient, a schedule of 5 visits per week was arranged. This consisted of a total of 35 adjustments during that 8-week period. All visits included adjustments, cryotherapy (to reduce inflammation and reduce discomfort during traction), and extension traction. On the 15th visit, the patient was instructed to begin extension cervical traction position at home. The time goal was to build to 20 minutes. On the 28th visit, a compressive force was added to the extension cervical traction in the office with a Regainer Chair (Promote Chiropractic, Saugus, MA). This protocol continued for the remainder of treatment, which consisted of 11 compression traction visits in addition to the above stated visit protocol.

On the 12th visit, the child's mother said that she noticed some positive changes in her son's general behavior. Before this time, his behavior was very problematic. On the 17th visit, the mother mentioned that she was noticing a decrease in the severity and frequency of the tics. On the 27th visit, the patient's mother informed the treating doctor that an appointment with the medical doctor concerning the Ritalin prescription was scheduled for that day. Based on the medical doctor's assessment at that time and his clinical experience, he felt that the patient was no longer exhibiting symptoms associated with ADHD. Consequently, he took him off the medications that he had been taking for 3 years. Throughout the balance of care, the patient continued to show steady behavioral improvement.

On the 35th visit, a follow-up lateral cervical radiograph was performed to assess any biomechanical changes in spinal configuration (Fig 2). The method of analysis was again the Harrison Posterior Tangent Method, which has been shown to be reliable in previous investigations.[16] Using the same analysis that was performed on the original radiographs, a significant biomechanical change was observed. The original measurement was +12° in a complete kyphotic configuration (127% from normal). The postfilm showed a near full cervical lordosis measuring at −32°. This new C2-7 angle represents only a 29% loss of lordosis from the ideal Harrison cervical spinal model,[17] which, besides health improvements, is used as the ultimate goal of care. During an 8-week treatment regimen, using the CBP protocol, an improvement of 42° between C2-7 was found in the pretreatment-posttreatment comparison for biomechanical configuration.

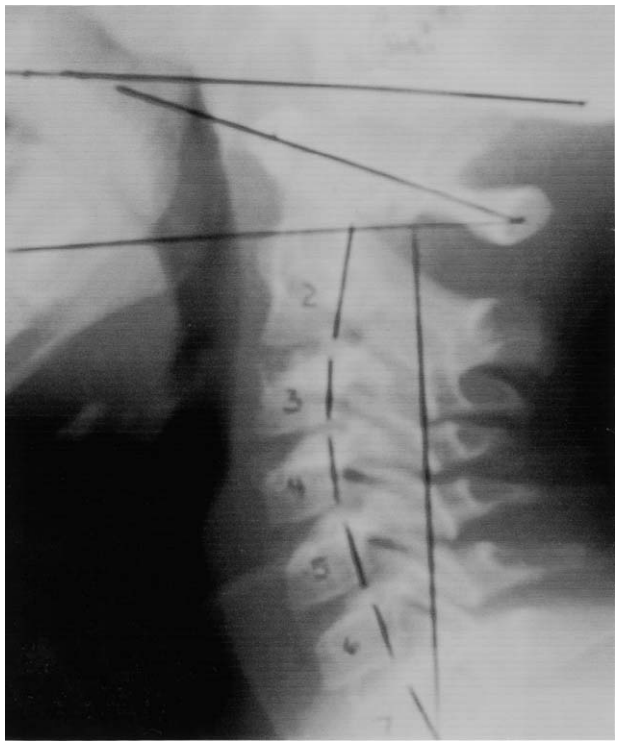

Fig 2. *This figure shows the posttreatment lateral cervical radiograph. The kyphosis seen previously now shows a cervical lordosis. The absolute rotation angle, measured as the intersection of posterior tangents on C2 and C7, equals 32°. The atlas plane line measured 22° from horizontal.*

After that point, the patient relocated with his family. A list of chiropractors who used CBP protocol was given to the patient before leaving the area, as well as instructions for ongoing home care. After follow-up telephone consultations during the next 3 months, the parents noted continued improvement of the residual symptoms. Up to that point, the family was not able to continue chiropractic care. The family then relocated again and we lost contact with them.

Discussion

There exists in the current biomedical literature an ideal cervical spinal model,[17] which was used as a goal of care in this case study. It is generally known in neurosciences and anatomy that the central nervous system is the master control system of the human body. It controls and coordinates all body and cellular functions. When we look at the literature today, there has been a significant amount of information published about the mechanical forces and tension placed on the spinal structures and cord tracts in various postures.[25-36]

Breig[26] showed the changes in spinal cord biomechanics from abnormal postural positions. We propose that these

changes in spinal canal and thus spinal cord position can cause such pathologic states as edema, hypoxia, blood loss, and cellular death.[28-36] It has been reported by some researchers that abnormal putamen and lenticular magnetic resonance imaging and positron-emission tomography have been observed in children with ADHD.[37,38] The previous refrences[28-36] may give insight to these abnormal scans. The underlying cause of the mechanical and thus physiologic changes in the spinal cord, brainstem, and higher brain centers are related to the abnormal static postural positions of the skull relative to the thorax.[26]

Mechanical compression of nerves can result in microvascular permeability changes in the endoneural capillaries and lead to neural edema and changes in impulse propagation.[28-36] Additionally, it has been shown that gradual decompression of nerve roots can restore the intrinsic blood flow.[36] Because the parents reported no other major traumatic injuries to the child other than a difficult birth, we propose that the cause of the abnormal spinal configuration was a result of difficult labor. Because of the vast amount of information concerning abnormal nerve function caused by mechanical stress in neck flexion (kyphosis),[26,39-45] it stands to reason, because his neck configuration was kyphotic, that the child's nervous system was not functioning properly. Through the restoration of normal biomechanical structure and curvature, these abnormal stresses and strains were removed from the cord, which led to the improvement in function.

There exists a large amount of literature on ADHD. This literature is generally pharmacologic and behavioral in nature. Many theories of causality and subsequent treatment have been put forth. However, because chiropractors are not authorized in most states to prescribe drugs, the pharmacologic information has little bearing for chiropractors. The chiropractors who treat patients with ADHD should, however, familiarize themselves with the current diagnostic and treatment protocols used by physicians. Medication may have an effect on treatment outcomes and may be an important factor in proper management of this condition.[1-15] It should be noted that these references are nowhere near a complete review of the literature on ADHD.

It is possible that the farther we move from the Harrison ideal spinal model,[17] the greater the neurologic stress from abnormal stress and strain on the spinal cord.[26] Restoring the cervical lordosis could be the most critical aspect of any chiropractic care protocol or clinical intervention. With specific mirror image adjusting, mirror image traction, and mirror image postural exercise, cervical curve restoration is now a possible outcome.[18-21]

Several limitations of this study include: (1) a possibility that there was spontaneous remission of the ADHD symptoms and that chiropractic care had no relevance to the symptom remission; (2) the patient may have been misdiagnosed by the medical doctor; and (3) the patient's parents may not have been reporting the retrospective symptoms accurately, giving a false sense of improvement. Because this is a case report, further research is needed to determine the true effects of CBP protocol on patients suffering with ADHD.

Conclusion

This case study shows that spinal correction using the CBP approach may have effects much greater than relief of musculoskeletal conditions. Altered spinal biomechanics associated with abnormal posture clearly relate to significant neurological stress and malfunction. This is particularly evident when considering the effects on the brainstem and the autonomic nervous system. Thus, even in obscure cases with systemic, organic, or chemical dysfunction like ADHD, we suggest optimal spine equals optimal health.

References

1. Whalen CK, Henker B. Attention-deficit/hyperactivity disorder. In: Ollendick TH, Hersen M, editors. Handbook of Child Psychopathy, ed 3. New York: Plenum; 1988. p. 181-211.
2. Still GF. Some abnormal psychical conditions in children. Lancet 1902;1:1008-12, 1077-82, 1163-8.
3. O'Callaghan MJ, Harvey JM. Biological predictors and comorbidity of attention deficit and hyperactivity disorder in extremely low birthweight infants at school. J Paediatr Child Health 1997;33:491-6.
4. Nyakas C, Buwalda B, Luiten PGM. Hypoxia and brain development. Prog Neurobiol 1996;49:1-51.
5. Thach BT. Maturation and transformation of reflexes that protect the laryngeal airway from liquid aspiration from fetal to adult life. Am J Med 2001;111(Suppl 8A);69S-77S.
6. American Psychiatric Association. Diagnostic and statistical manual of mental disorders. 4th ed. Washington (DC): American Psychiatric Association; 2000. p. 86-102.
7. Douglas VI. Cognitive control processes in attention-deficit/hyperactivity disorder. In: Quay HC, Horgan A, editors. Handbook of disruptive behavior disorders. New York: Plenium; 1999. p. 105-38.
8. Barkley RA. Issues in the diagnosis of attention-deficit/hyperactivity disorder in children. Brain Dev 2003;25:77-83.
9. Dupaul GJ, Barkley RA. Situational variability of attention problems: psychometric properties of Revised Home and School Situations Questionnaires. J Clin Child Psychol 1992; 21:178-88.
10. Altpeter TS, Breen MJ. Situational variation in problem behavior at home and school in attention deficit disorder with hyperactivity: a factor analytic study. J Child Psychol Psychiatry 1992;33:741-8.
11. Harvey WJ, Reid G. Motor performance of children with attention-deficit/hyperactivity disorder: a preliminary investigation. Adapted Phys Act Q 1997;14:189-202.
12. Kadesjo B, Gillberg C. The comorbidity of AHDH in the general population of Swedish school-age children. J Child Psychol Psychiatry 2001;42:487-92.
13. Klorman R, Hazel-Fernandez H, Shaywitz SE, Fletcher JM, Marchione KE, Holahan JM, et al. Executive function deficits in attention-deficit/hyperactivity disorder are independent of oppositional defiant or reading disorder. J Am Acad Child Adolesc Psychiatry 1999;38:1148-55.

14. Rapport MD, Moffit C. Attention deficit/hyperactivity disorder and methylphenidate: a review of height/weight, cardiovascular, and somatic complaint side effects. Clin Psychol Rev 2002; 22:1107-31.
15. Bussing R, Zima BT, Belin TR. Variations in ADHD treatment among special education students. J Am Acad Child Adolesc Psychiatry 1998;37:968-76.
16. Harrison DE, Harison DD, Cailliet R, Troyanovich SJ, Janik TJ, Holland B. Cobb method or Harrison posterior tangent method: which to choose for lateral cervical radiographic analysis. Spine 2000;25:2072-8.
17. Harrison DD, Janik TJ, Troyanovich SJ, Holland B. Comparisons of lordotic cervical spine curvatures to a theoretical ideal model of the static sagittal cervical spine. Spine 1996;21:667-75.
18. Harrison DD, Jackson BL, Troyanovich SJ, Robertson GA, DeGeorge D, Barker WF. The efficacy of cervical extension-compression traction combined with diversified manipulation and drop table adjustments in the rehabilitation of cervical lordosis. J Manipulative Physiol Ther 1994;17:454-64.
19. Harrison DE, Harrison DD, Betz J, Janik TJ, Holland B, Colloca C. Increasing the cervical lordosis with CBP seated combined extension-compression and transverse load cervical traction with cervical manipulation: non-randomized clinical control trial. J Manipulative Physiol Ther 2003;26:139-51.
20. Harrison DE, Cailliet R, Harrison DD, Janik TJ, Holland B. A new 3-point bending traction method for restoring cervical lordosis and cervical manipulation: a nonrandomized clinical controlled trial. Arch Phys Med Rehabil 2002;83:447-53.
21. Harrison DE, Harrison DD, Hass J. CBP structural rehabilitation of the cervical spine. 1st ed. Evanston (WY): Harrison CBP Seminars; 2002. p. 91-146.
22. Harrison DD, Janik TJ, Harrison GR, Troyanovich S, Harrison DE, Harrison SO. Chiropractic biophysics technique: a linear algebra approach to posture in chiropractic. J Manipulative Physiol Ther 1996;19:525-35.
23. Harrison DD. CBP technique: the physics of spinal correction. National Library of Medicine #WE 725 4318C. Evanstown (KY): Harrison CBP Seminars; 1981-97. p. 1-45.
24. Troyanovich SJ, Buettner M. A structural chiropractic approach to the management of diffuse idiopathic skeletal hyperostosis. J Manipulative Physiol Ther 2003;26:202-6.
25. Panjabi M, White A. Biomechanics of nonacute cervical spinal cord trauma. Spine 1988;13:838-42.
26. Breig A. Adverse biomechanical tension in the central nervous system. Analysis of cause and effect. Relief by functional neurosurgery. New York: John Wiley and Sons; 1978. p. 14-36.
27. Wyke BD. Articular neurology and manipulative therapy. In: Idezak Rm, editor.Aspects of manipulative therapy. New York: Churchill Livingston; 1985. p. 72-7.
28. Kobayashi S, Yoshizawa H, Hachiya S, Ukai T, Morita T. Vasogenic edema induced by compression injury to the spinal nerve root. Distribution of intravenously injected protein tracers and gadolinium-enhanced magnetic resonance imaging. Spine 1993;18:1410-24.
29. Matsui T, Takahashi K, Moriya M, Tanaka S, Kawahara N, Tomita K. Quantitative analysis of edema in the dorsal nerve roots induced by acute mechanical compression. Spine 1998; 23:1931-6.
30. Kikuchi S, Konno S, Kayama S, Sato K, Olmarker K. Increased resistance to acute compression injury in chronically compressed spinal nerve roots. An experimental study. Spine 1996;21:2544-50.
31. Olmarker K, Rydevik B, Holm S, Bagge U. Effects of experimental compression on blood flow in spinal nerve roots. A vital microscopic study on the porcine cauda equine. J Orthop Res 1989;7:817-23.
32. Olmarker K, Rydevik B, Holm S. Edema formation in spinal nerve roots induced by experimental, graded compression. An experimental study on the pig cauda equine with special reference to differences in effects between rapid and slow onset of compression. Spine 1989;14:569-73.
33. Rydevik B, Brown MD, Lundborg G. Pathoanatomy and pathophysiology of nerve root compression. Spine 1984;9: 7-15.
34. Matsui H, Olmarker K, Cornefjord M, Takahashi K, Rydevik B. Local electrophysiologic stimulation in experimental double level cauda equine compression. Spine 1992;17:1075-8.
35. Olmarker K, Holm S, Rydevik B. Importance of compression onset rate for the degree of impairment of impulse propagation in experimental compression injury of the porcine cauda equine. Spine 1990;15:416-9.
36. Olmarker K, Holm S, Rydevik B, Bagge U. Restoration of intrinsic blood flow during gradual decompression of the porcine cauda equine. Neuro-Orthopedics 1991;10:83-7.
37. Singer HS, Reiss AL, Brown JE. Volumetric MRI changes in basal ganglia of children with Tourett's syndrome. Neurology 1993;43:950-6.
38. Brandeis D, van Leeuwen TH, Rubia K, Vitacco D, Steger J, Pascual-Marqui RD, Steinhausen H-C. Neuroelectric mapping reveals precursors of failures to stop in Children with attention deficits. Behav Brain Res 1998;94:111-25.
39. Breig A, El-Madi A. Biomechanics of the cervical spinal cord. Relief of contact pressure on and overstretching of the spinal cord. Acta Radiol 1966;4:602-24.
40. Breig A, Turnbull I, Hassler O. Effects of mechanical stresses on the spinal cord in cervical spondylosis. A study on fresh cadaver material. J Neurosurg 1966;25:45-56.
41. Breig A. Biomechanics of the central nervous system. Stockholm: Almqvist and Wiksell; 1960.
42. Breig A. Skull traction and cervical cord injury. A new approach to improved rehabilitation. New York: Springer-Verlag; 1989. p. 1-15.
43. Breig A, Renard M, Stefanko S, Renard C. Anatomic bases of medical and surgical techniques. Healing of the severed spinal cord by biomechanical relaxation and surgical immobilization. Anat Clin 1982;4:167-81.
44. Breig A. Pathological stress in the pons-cord tissue tract and its alleviation by neurosurgical means. Clin Neurosurg 1973;20: 85-94.
45. Breig A. Overstretching of and circumscribed pathological tension in the spinal cord. A basic cause of symptoms in cord disorders. J Biomech 1970;3:7-9.